



# Optical Flow with Theoretically Justified Warping Applied to Medical Imaging

Anke Meyer-Baese, Joan Massich, Guillaume Lemaître, Mojdeh Rastgoo

## ► To cite this version:

Anke Meyer-Baese, Joan Massich, Guillaume Lemaître, Mojdeh Rastgoo. Optical Flow with Theoretically Justified Warping Applied to Medical Imaging. Breast Image Analysis Workshop (BIA), Medical Image Computing and Computer Assisted Interventions (MICCAI) 2015, Oct 2015, Munich, Germany. hal-01235869

**HAL Id: hal-01235869**

**<https://u-bourgogne.hal.science/hal-01235869>**

Submitted on 3 Dec 2015

**HAL** is a multi-disciplinary open access archive for the deposit and dissemination of scientific research documents, whether they are published or not. The documents may come from teaching and research institutions in France or abroad, or from public or private research centers.

L'archive ouverte pluridisciplinaire **HAL**, est destinée au dépôt et à la diffusion de documents scientifiques de niveau recherche, publiés ou non, émanant des établissements d'enseignement et de recherche français ou étrangers, des laboratoires publics ou privés.

# Optical Flow with Theoretically Justified Warping Applied to Medical Imaging

Anke Meyer-Baese, Joan Massich, Guillaume Lemaitre and Mojdeh Rastgoo

No Institute Given

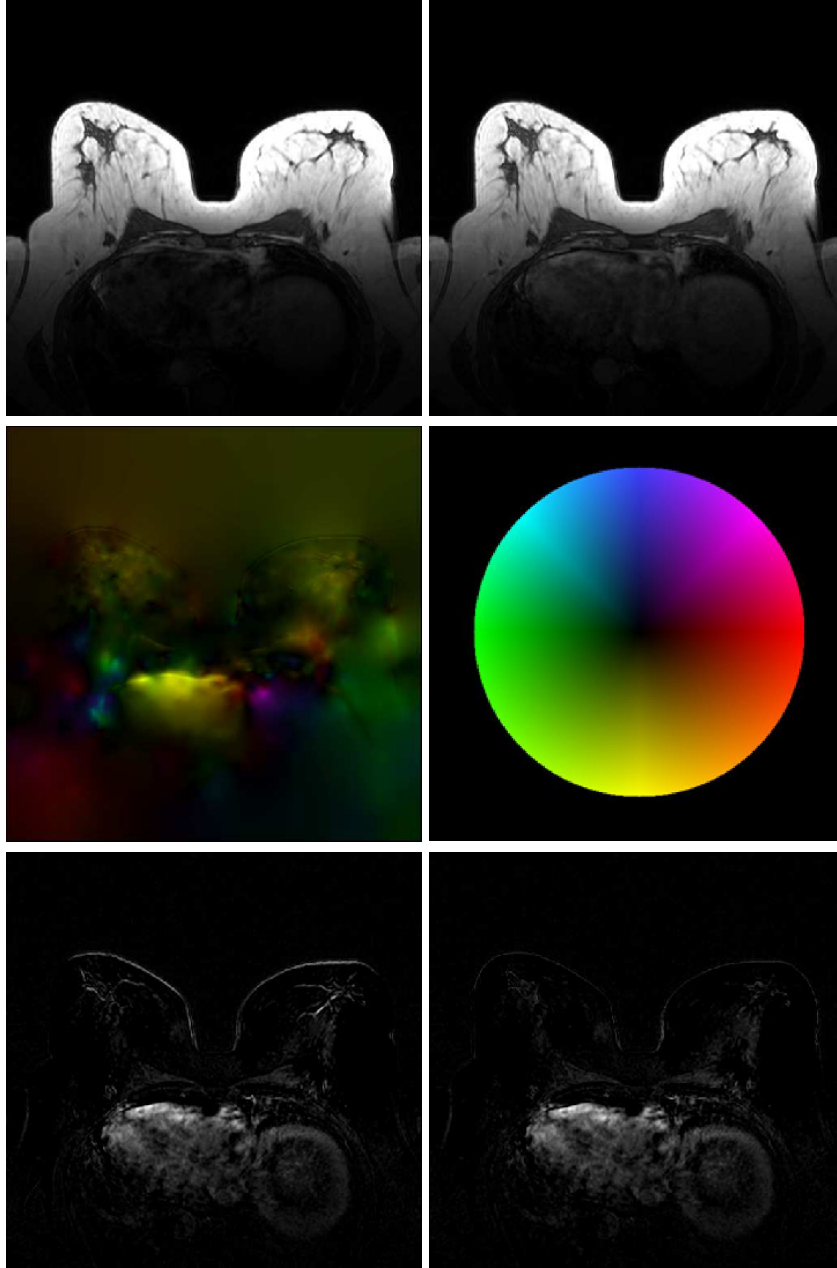
**Abstract.** Motion induced artifacts represent a major obstacle in the correct malignant lesion detection in medical imaging especially in MRI. The goal of this paper is to evaluate the performance of a new non-rigid motion correction algorithm based on the optical flow method. The proposed algorithm specifically addresses three major problems in MRI: the induced gaps in 3D images, the constancy assumption of current optical flow algorithms and the existence of large non-linear movement. In this paper, we compare the performance of extracted kinetic features from the tumor regions under consideration of several 2-D or 3-D motion compensation parameters for the differential diagnosis of enhancing lesions in breast MRI. Based on several simulation results, we determined the optimal motion compensation parameters and showed that the proposed motion compensation algorithm can improve the correct lesion detection.

**Keywords:** Optical Flow, Medical Imaging, MRI, Motion Compensation

## 1 Introduction

Dynamic contrast-enhanced magnetic resonance imaging (DCE-MRI) represents an established method for the detection and diagnosis of breast lesions. However to obtain a correct localization of the lesions in these images is quite challenging since motion artifacts and changes in the breast shape are quite common during this procedure. An elastic matching algorithm represents an important prerequisite for the registration of dynamic MR image series. Therefore, spatial registration has to be performed before enhancement curve analysis. Due to the elasticity and heterogeneity of breast tissue, only nonrigid image registration methods are suitable. Although there has been a significant amount of research on non-rigid motion compensation techniques in brain imaging, few methods have been so far proposed for breast MRI. Most proposed techniques employ physically motivated deformation models [3, 4], transformations based on the deformation of B-splines [5, 6], elastic transformations [7, 8] and more recently adaptive grid generation algorithms [9].

In this paper, we develop a novel motion compensation algorithm to reduce these motion artifacts as is exemplarily shown in Figure 1. Further to test the applicability of this algorithm in computer-aided diagnosis, we will extract kinetic features from the lesions and evaluate the impact of the motion compensation algorithm on the automated tumor detection.



**Fig. 1.** Removing bright stripes from the difference image by motion compensation. (a) **Top left:** frame 1 of 5 post-contrast images. (b) **Top right:** frame 4 of 5 post-contrast images. (c) **Middle:** Computed motion. The color depicts the direction of movement, the brightness the (relative) velocity. (d) Colorcode of movement. The color depicts the direction of movement, the brightness the (relative) velocity. For a better visibility, the brightness is normed. (e) **Bottom left:** difference image (b) - (a) without motion compensation. (f) **Bottom right:** difference image (b)-(a) with motion compensation. Parameters:  $\sigma = 1.8$ ,  $\mu = 100$ ,  $\lambda = -50$ ;

## 2 Optical Flow of Horn & Schunck and Improvements in Data and Smoothness Term

Mathematically, a 3D MR image  $f$  is a continuous function from the bounded domain  $\Omega \subset \mathbb{R}^3$  to the real numbers

$$f : \Omega \rightarrow \mathbb{R}, \quad (1)$$

where the gray values  $f(x, y, z)$  describe the brightness of one voxel and correspond to the detected spin echo at this place. For the computation of the optical flow we use the method of Horn & Schunck [10], since it overcomes the aperture problem, provides sub pixel accuracy and has proven to provide good results in [16] and can easily be adapted and enhanced [2]. The original model has been developed for 2D and is extended here to for the 3D case.

The basic method of Horn & Schunck works very well with standard optic flow problems [10], but it can be improved by adapting the data and smoothness term in a given application [12, 14]. As indicated above one can replace the constancy assumption of the gray values by the same assumption about the image gradient which makes the data term independent of global intensity changes. Furthermore it is possible to adapt the smoothness term when there is some apriori knowledge about the expected motion. Until now we have expected any motion to be smooth, because it is unlikely that adjacent voxels are moving completely in different directions. Additionally, we know that no part of the regular breast tissue is supposed to disappear or to be generated during the MRI and since regular tissue is highly elastic we would like to penalize non-divergence-free flow fields. This can be done by adding an additional smoothness term,  $(div(u, v, w))^2 = (u_x + v_y + w_z)^2$ :

$$\begin{aligned} E(u, v, w) = & \int_{\Omega} \mathbf{u}^T J(f) \mathbf{u} + \mu(|\nabla u|^2 + |\nabla v|^2 + |\nabla w|^2) \\ & + (\lambda + \mu)(u_x + v_y + w_z)^2 dx dy dz. \end{aligned} \quad (2)$$

$J$  represents the motion tensor. The first term on the right hand side of the equation represents the linearized data term while the second describes a penalizer for roughness and the third one for divergence. In order to find the minimizers of our new functional (2), we have to solve the corresponding Euler-Lagrange equations again, which are also known as the Navier-Lamé equations or the strong form of the elasticity equations [15].

The approach with this elastic regulariser has proven to lead to good results in registering images, especially in MR images.

## 3 Challenges and Corresponding Solutions of the Standard Model

A non-rigid motion compensation algorithm in breast MRI has to overcome three major obstacles in order to be applicable in the clinical environment.

The first problem simply is a limitation due to the MRI technology. A 3D image consists of many consecutive 2D slices  $i(f(\cdot, \cdot, i))$  that are taken one after another and quite often the boundaries of these slices are not matching each other perfectly. These induced gaps in the 3D image can lead to a degradation in quality of the motion field when one tries to compute the flow across adjacent slices. Assuming an insignificant motion in the  $z$  direction, we simplify the functional (2).


The next problem arises from injecting the contrast agent. Especially in the tumor region, where we want the most exact movement computation, the constancy assumption is failing. Since the tumor is uptaking faster the contrast agent than the surrounding tissue, the tumor is suddenly appearing and therefore this is violating any kind of local constancy assumption. This can be solved by masking the tumor region so that the data term is not a factor in this area.

The optical flow obtained for the masked regions is only depending on the movement of the surrounding tissue due to the filling in effect guaranteed by the smoothness term. This is a good approximation since the displacement of the tumor depends directly on the movement of the whole breast, and the resulting flow field in this area is smooth and almost divergence-free (see Figure 2).

The last problem that can be noticed is the linearisation of the data term by a Taylor expansion. If we consider the fact that large non-linear movement is possible, the Taylor expansion is not precise enough and this yields an inaccurate data term. To avoid this we don't linearize the constancy assumption and keep the original quadratic term. This results in a possibly non-convex energy functional and therefore the minimization is no longer trivial due to possible multiple local minima. We address this problem by using a warping strategy. This means we consider our minimization problem on a coarse scale where a linearisation makes sense again because large movements become small movements on a coarse grid. There we solve it in the common way and use the solution to compensate the movement on this grid. Then we warp this image back to the next finer grid where we compute the motion again. We continue like this until we reach the finest, the original resolution. This strategy brings us step by step closer to the global minimum.

## 4 Evaluation of the Motion Compensation Technique in Breast MRI Lesion Diagnosis

The database consists of 63 patients, all female and age range 42-73, and has 66 solid breast tumors. Histologic findings were malignant in 30 and benign in 36 lesions. Tumors were classified as diagnostically challenging lesions as both foci and non-mass-enhancing lesions. Lesion size was derived from mammography images. Mean size of malignant lesions was 1.3 cm and mean size of benign lesions was 1.2 cm. MRI was performed with a 1.5 T system (Magnetom Vision, Siemens, Erlangen, Germany) with two different protocols equipped with a dedicated surface coil to enable simultaneous imaging of both breasts.



**Fig. 2.** Masking of regions. (a) **Top left:** frame 3 of post-contrast series with mask. (b) **Top right:** segmented tumor. (c) **Bottom left:** flow computed without mask. **Bottom right:** flow computed with mask. Parameters:  $\sigma = 1.8, \mu = 500, \sigma = -500$

Motion compensation is followed by the image segmentation where each MR image has to be segmented into two regions, the region of interest (ROI), i.e. the voxels belonging to the tumor, and the background. We are using an interactive region growing algorithm that creates a binary mask for the tumor and its surroundings. The image used for the region growing algorithm was the difference image of the second post-contrast image and the native pre-contrast image.

For each lesion we extract kinetic features representing the slope of the relative signal intensity enhancement (RSIE). In [11] was shown that the shape of the time-signal intensity curve represents an important criterion in differentiating benign and malignant enhancing lesions in DCE-MR imaging. Since this feature has already proven it's descriptive power we are using it in the evaluation of motion correction. We use different classification methods [17, 18] to evaluate the effect of motion compensation to breast MRI images as shown in Table 1.

LDA	Linear Discriminant Analysis.
NLDA	Naive Bayes Linear Discriminant Analysis.
QDA	Quadratic Discriminant Analysis.
NQDA	Naive Bayes Quadratic Discriminant Analysis.
FLD	Fisher's Linear Discriminant Analysis.
PK	SSVM Classification with a Polynomial Kernel.
RBF	SVM Classification with a Radial Basis Function.
PUK	SVM Classification with a Pearson VII Universal Function Kernel.

**Table 1.** Classifiers employed for lesion classification.

Table 2 shows the results for different classifiers and kinetic features described by the slope of the RSIE when applied to tumor classification. The results reveal that motion compensation based on the proposed algorithm has the power to significantly improve lesion detection in breast MRI.

mot. comp. parameter		LDA	QDA	FLD	PK	NPK	RBF	PUK
no compensation		71.6	71.6	71.3	64.2	47.9	71.3	70.1
2D	$\sigma = 1, \mu = 100, \lambda = -100$	67.2	70.1	72.4	64.2	47.9	70.1	68.7
	$\sigma = 1, \mu = 100, \lambda = -50$	76.1	73.1	76.1	64.2	47.9	76.1	74.6
	$\sigma = 3, \mu = 100, \lambda = -100$	73.1	74.1	74.1	73.1	55.0	74.1	73.9
	$\sigma = 3, \mu = 100, \lambda = -50$	79.5	76.1	75.6	75.6	47.9	79.5	79.5
3D	$\sigma = 1, \mu = 100, \lambda = -100$	76.3	74.6	74.6	72.4	47.9	74.6	73.1
	$\sigma = 1, \mu = 100, \lambda = -50$	67.2	70.1	61.2	76.1	48.5	74.6	73.1
	$\sigma = 3, \mu = 100, \lambda = -100$	70.1	72.1	61.2	61.9	47.9	74.6	73.1
	$\sigma = 3, \mu = 100, \lambda = -50$	68.7	66.0	72.1	58.2	47.9	68.7	66.0

**Table 2.** AUC for the classifiers applied to the slope of the RSIE

## 5 Conclusion and Discussion

Breast MRI reading is often affected by motion artifacts of different grades. Motion compensation becomes therefore imperative in the clinical environment of breast MRIs in order to improve the diagnostic value of mammography reading. We developed a new motion compensation algorithm based on the Horn and Schunck method that addresses the necessary requirements for application in MRI and determined the optimal parameters for lesion diagnosis when kinetic features were considered. The optimal motion correction results were achieved for motion compensation in two directions for mostly small standard deviations of the Gaussian kernel and smoothing parameter. An explanation of this behavior is because the induced gaps in the three-dimensional images lead to a degradation of the motion field when the flow is computed across adjacent slides. The performed ROC-analysis shows that an integrated motion compensation step in a CAD system represents a valuable tool for supporting radiological diagnosis in dynamic breast MR imaging.

## References

1. S. Behrens, H. Laue, T. Boehler, B. Kuemmerlen, H. Hahn, and H. O. Peitgen. Computer assistance for mr based diagnosis of breast cancer: Present and future challenges. *Computerized Medical Imaging and Graphics*, 31:236–247, 2 2007.
2. Andrés Bruhn, Joachim Weickert, Christian Feddern, Timo Kohlberger, and Christoph Schnorr. Variational optical flow computation in real time. *Image Processing, IEEE Transactions on*, 14(5):608–615, 2005.
3. A. Hill, A. Mehnert, S. Crozier, and K. McMahon. Evaluating the accuracy and impact of registration in dynamic contrast-enhanced breast mri. *Concepts in Magnetic Resonance Part B*, 35B:106–120, 2 2009.
4. W. Crum, C. Tanner, and D. Hawkes. Anisotropic multi-scale fluid registration: evaluation in magnetic resonance breast imaging. *Physics in Medicine and Biology*, 50(4):5153–5174, 2005.
5. T. Rohlfing, C. Maurer, D. Bluemke, and M. Jacobs. Volume-preserving nonrigid registration of MR breast images using free-form deformation with an incompressibility constraint. *Medical Imaging, IEEE Transactions on*, 22(2):730–741, 2003.
6. D. Rueckert, L. Sonoda, C. Hayes, D. Hill, M. Leach, and D. Hawkes. Nonrigid registration using free-form deformations: Application to breast MR images. *Medical Imaging, IEEE Transactions on*, 18(2):712–721, 1999.
7. R. Lucht, S. Delorme, J. Heiss, M. Knopp, M. A. Weber, J. Griebel, and G. Brix. Classification of Signal-Time Curves Obtained by Dynamic-Magnetic Resonance Mammography. *Artificial Intelligence*, 114(6):125–156, 1999.
8. P. Hayton, M. Brady, S. Smith, and N. Moore. A non-rigid registration algorithm for dynamic breast MR images. *Investigative Radiology*, 40(7):442–447, 2005.
9. M. Chu, H. Chen, C. Hsieh, T. Lin, H. Hsio, L. Liao, and Q. Peng. Adaptive Grid Generation Based Non-rigid Image Registration using Mutual Information for Breast MRI. *Journal of SIGNAL PROCESSING SYSTEMS for Signal, Image, and Video Technology*, 3:45–63, 2009.
10. Berthold K.P. Horn and Brian G. Schunck. Determining optical flow. *Artificial Intelligence*, 17(1-3):185 – 203, 1981.