

Major intra-familial phenotypic heterogeneity and incomplete penetrance due to a *CACNA1A* pathogenic variant

Chloé Angelini^{1§}, Julien Van Gils^{1§}, Antoine Bigourdan², Pierre-Simon Jouk³, Didier Lacombe¹, Patrice Menegon², Sébastien Moutton⁴, Florence Riant⁵, Guilhem Sole⁶, Elisabeth Tournier-Lasserve⁵, Aurélien Trimouille¹, Marie Vincent⁷, Cyril Goizet^{1,8}.

¹Service de Génétique Médicale, CHU de Bordeaux and Laboratoire MRGM, INSERM U1211, Univ. Bordeaux, Bordeaux, France

²Service de neuroradiologie, CHU de Bordeaux, France

³Service de génétique médicale, CHU de Grenoble, France

⁴Service de génétique médicale, CHU de Dijon, France

⁵Service de génétique moléculaire, Hôpital Lariboisière, Paris, France

⁶Service de neurologie médicale, CHU de Bordeaux, France

⁷Service de génétique médicale, CHU de Nantes, France.

⁸Centre de référence neurogénétique, Service de génétique médicale, CHU de Bordeaux, France

§ : both authors contributed equally to this work

Corresponding author: Chloe Angelini

Abstract

The *CACNA1A* gene encodes a calcium-dependent voltage channel, localized in neuronal cells. Pathogenic variants in this gene are known to lead to a broad clinical spectrum including episodic ataxia type 2, spinocerebellar ataxia type 6, familial hemiplegic migraine, and more recently epileptic encephalopathy. We report a large family revealing a wide variability of neurological manifestations associated with a *CACNA1A* missense pathogenic variant. The index case had early-onset epileptic encephalopathy with progressive cerebellar atrophy, although his mother and his great-grandmother suffered from paroxysmic episodic ataxia. His grandfather and great grand-aunt reported no symptoms, but two of her sons displayed early-onset ataxia with intellectual disability. Two of her little daughters suffered from gait disorders, and also from epilepsy for one of them. All these relatives were carriers of the previously described heterozygous variant in *CACNA1A* gene. We report here the first family leading to major clinical variability and incomplete penetrance. Our family highlights the difficulties to provide accurate genetic counselling concerning prenatal diagnosis regarding highly variable severity of the clinical presentation.

Keywords

Epileptic encephalopathy

CACNA1A

Incomplete penetrance

Ataxia

Genetic counselling

Clinical reports

Introduction

The *CACNA1A* gene (MIM*601011) is located at 19p13.13 and encodes the voltage-dependent P/Q-type calcium channel subunit alpha-1A [Baloh et al. 1997]. Voltage dependent calcium channels mediate the entry of calcium ions into excitable cells, and are involved in multiple calcium dependent processes, such as muscle contraction, hormone and neurotransmitter release or gene expression. Heterozygous pathogenic variants in *CACNA1A* may lead to several different phenotypes, including episodic ataxia type 2 (EA2, MIM#108500) [Ophoff et al. 1996], familial hemiplegic migraine (FHM1, MIM#141500) [Ophoff et al. 1996] and spinocerebellar ataxia type 6 (SCA6, MIM#183086) [Zhuchenko et al. 1997]. Overlapping clinical features to the allelic disorders FHM1 and EA2 have been described [Ducros et al. 1999], and patients with SCA6 may occasionally display characteristic features of EA2 [Barros et al. 2013]. The recent description of epileptic encephalopathy and cognitive impairment in patients has enlarged the clinical spectrum of *CACNA1A*-related disorders [Damaj et al. 2015] [Hayashida et al. 2018].

Herein, we describe a large family in whom segregated a heterozygous missense pathogenic variant in *CACNA1A*. Clinical presentation was highly variable from one relative to another, with a phenotype ranging from no feature to severe epileptic encephalopathy with cerebellar atrophy.

Index patient

Patient IV.1. (Fig. 1) is the first child of non-consanguineous french parents. Pregnancy and delivery were uneventful. He was born at term, weighed 3520g, measured 51cm and his head circumference was 37cm. Apgar score was assessed at 10 out of 10 at 1 and 5 minutes after birth. He early experienced feeding difficulties with severe axial hypotonia and important developmental delay. Head control was acquired at age one year, he was able to sit alone at 19 months, to stand up at 20 months, and walk without support at 3.5 years, but still presented ataxic gait, hypotonia and important drooling. He started babbling at 10 months and pronounced his first words at 18 months.

A first brain MRI was normal at 16 months. Diffused slow waves with no epileptic spikes were observed on electroencephalogram at 16 months. Parents reported first occurrence of generalized seizures at 3.5 years, described as convulsions of the four limbs associated with a transitory loss of consciousness, lasting for five minutes, and then yielding to an important weakness. An intercritical electroencephalogram was performed and was normal. At age of 4.5 years, EEG found diffused slow waves when awake and few rolandic epileptic spikes during sleep. Introduction of oxcarbazepine led to a drastic diminution of the seizures, still presenting myoclonia and absence seizures in the morning. Brain MRI was controlled and found a progressive cerebellar atrophy, predominant on the vermis (Fig.2).

At age 5.5 years, the patient had severe truncal hypotonia, 4 limbs hypertonia and absence of any speech. There were neither evident pyramidal or extrapyramidal signs, nor nystagmus. Facial nerves examination was normal. No facial dysmorphic criteria were found.

Ophthalmological examination was normal, and audiogram showed a moderate conductive deafness. Metabolic investigations were normal (amino acids and organic acids chromatography, in the blood, urines and cerebrospinal fluid (CSF), sialotransferrin electrophoresis, CDG syndrome, vitamin E, seric copper). Routine CSF analysis was also normal. First-line genetic analyses including *DMPK*, *FMR1*, and CGH-array were normal.

Family relatives

Patient III.2, aged 35, experienced daily episodic gait ataxia with dysarthria and vertigo since age 10 years. These episodes mostly occur in the morning, after physical exercise and resolved spontaneously in a few hours. Acetazolamide medication (250mg per day) introduced at age 34 considerably improved the frequency of these episodes (about once a week). She doesn't experience interictal signs, such as nystagmus or gait ataxia. Physical examination between gait ataxia episodes was normal. Brain-MRI, performed at age 35, [did not](#) show cerebellar atrophy.

Patient I.2, aged 76, reported occasional isolated ataxic gait since age 30. These episodes occurred rarely, about once a week, and could lead to falls. She didn't feel embarrassed by these balanced disorders.

Patients II.3 and II.4 suffered from stable early-onset cerebellar ataxia, dysarthria and nystagmus since their childhood. They presented epileptic seizures during their childhood that yielded spontaneously. Brain-MRI revealed cerebellar atrophy. Both had mild intellectual disability, they pronounced their first words at 3 years and walked independently at 5 years. They had educative support in a specialized institute. At the age of 30 and 33, respectively, they still lived with their parents, and worked in adapted structures.

Patient III.3, aged 24, presented permanent gait disorders since age 3,5. She has been treated with acetazolamide since age 20, without any clear improvement over time. Patient III.4, aged 22, presented gait disorders associated with partial epilepsy since childhood. Topiramate medication led to an arrest of the seizures and acetazolamide medication reduced the intensity of gait disorders. Brain MRI also found a cerebellar atrophy in patients III.3 and III.4.

Patients I.3, II.2 and II.5 show total absence feature at age 70, 40 and 54 respectively. They were carefully examined by an expert neurologist.

Molecular and genetic analysis

Direct sequencing of *CACNA1A* gene in the index case led to identify a heterozygous missense pathogenic variant NM_023035.2: c.835C>T, p.(Arg279Cys) in exon 6 (ClinVar, SCV000778839.1). This variant segregated in all the affected relatives as well as in three asymptomatic relatives (subjects I.3, II.2 and II.5). The percentage of penetrance in this family is 70% (n=7/10). All of the in silico prediction programs predicted this variant to be deleterious, supported by the high CADD score of 32 [Kircher et al. 2014]. This variant has already been reported in familial episodic ataxia type 2 [Maksemous et al. 2016], and is absent from GnomAD and ExAc database.

Discussion

Originally, pathogenic variants in *CACNA1A* gene have been associated with variable presentations of cerebellar ataxia and hemiplegic migraine [Ophoff et al. 1996]. The phenotype of epileptic encephalopathy has been associated only recently with pathogenic variants in this gene [Damaj et al. 2015] [Hayashida et al. 2018]. Four families with affected relatives who may suffer from either epileptic encephalopathy, episodic ataxia type 2 or other neurocognitive manifestations caused by truncating *CACNA1A* variants have been first reported [Damaj et al. 2015]. More recently, five sporadic patients with epileptic encephalopathy caused by a *de novo* heterozygous missense variant were described [Epi4K Consortium 2016]. In addition, a severe phenotype of epileptic encephalopathy with progressive cerebral, cerebellar and optic nerves atrophy was also associated to biallelic variants of *CACNA1A* in two sibs [Reinson et al. 2016].

We report a wide variability of features among relatives carrynig a *CACNA1A* missense pathogenic variant. The carriers of the variant may alternatively display severe epileptic encephalopathy or episodic ataxia or cerebellar ataxia with intellectual deficiency. Interestingly, three relative carriers of the pathogenic variant showed total absence of features, clearly indicating incomplete penetrance. Such incomplete penetrance has been previously suggested in two families [Epi4K Consortium 2016]. Indeed, a *CACNA1A* pathogenic variant inherited from an asymptomatic mother was already reported, but it was a maternal mosaicism. Damaj *et al.* also reported a family with an apparent incomplete penetrance, encompassing EA2 and epilepsy, but clinical examination was not performed among the patients that didn't present symptoms [Damaj et al. 2015]. Our data suggest that the lack of penetrance associated with *CACNA1A*-related disorders has probably been underestimated.

Functional studies have been done in mouse thalamic relay neurons to explore the effect of different pathogenic variants in *CACNA1A* gene. They found that pathogenic variants in high-voltage-activated Ca²⁺ channels subunits stimulate low-voltage-activated Ca²⁺ channels [Zhang et al. 2002]. But these

channels are not as efficient as high voltage Ca^{2+} channels. It leads at a cellular level to synaptic dysfunction and clinically to pathological manifestations. High voltage calcium channels are expressed, among other organs, in the cerebellum, thalamus, cortex and hippocampus. The different localizations of this channel may explain the variability of the penetrance and neurological symptoms presented in patients with *CACNA1A* pathogenic variants.

The issue of prenatal diagnosis is sensitive regarding the broad clinical spectrum and the potential incomplete penetrance. Some carriers of the *CACNA1A* pathogenic variant report no symptoms, other present episodic ataxia and others have major developmental delay due to epileptic encephalopathy. Modifier genes or factors that could influence the pathogenicity of *CACNA1A* pathogenic variants are yet unknown. Genetic counseling in these families is therefore extremely challenging.

Aknowledgements

We thank the family for their cooperation.

Figures legends

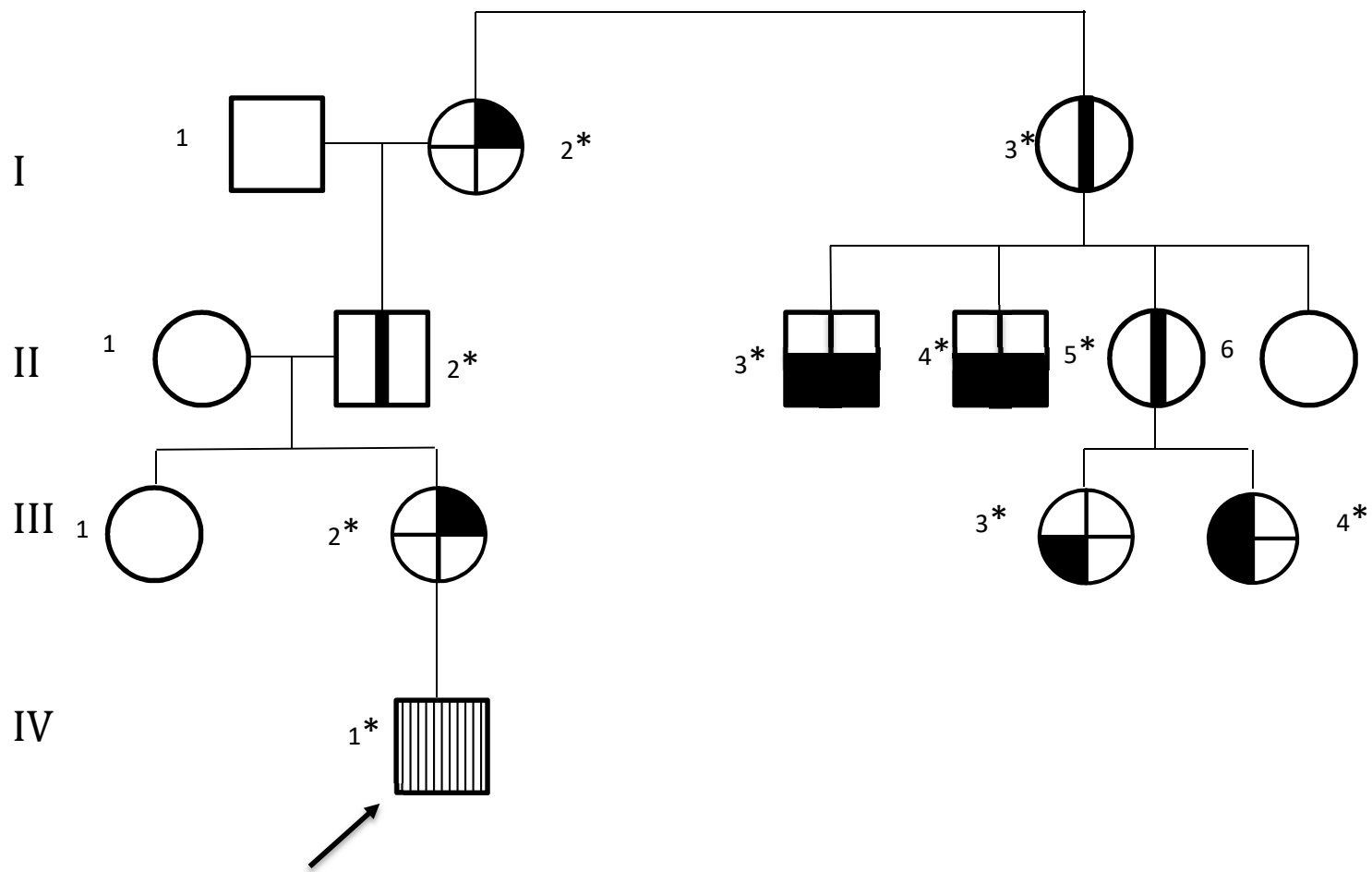
Fig 1. Pedigree. The family comprised of ten carriers of the *CACNA1A* pathogenic variants, with three asymptomatic carriers, from four generations.



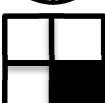



Fig 2. T1 Sagittal cross sectional brain MRI of index patient IV.1, with hypoplasia of the vermis

References

- Baloh, Robert, Qing, Furman, and Nelson. 1997. 'Familial Episodic Ataxia: Clinical Heterogeneity in Four Families Linked to Chromosome 19p'. *Annals of Neurology* 41 (1): 8–16. <https://doi.org/10.1002/ana.410410105>.
- Barros, José, Damásio, Tuna, Alves, Silveira, Pereira-Monteiro, Sequeiros, Alonso, Sousa, and Coutinho. 2013. 'Cerebellar Ataxia, Hemiplegic Migraine, and Related Phenotypes Due to a *CACNA1A* Missense Mutation: 12-Year Follow-up of a Large Portuguese Family'. *JAMA Neurology* 70 (2): 235–40. <https://doi.org/10.1001/jamaneurol.2013.591>.
- Damaj, Lena, Lupien-Meilleur, Lortie, Riou, Ospina, Gagnon, Vanasse, and Rossignol. 2015. '*CACNA1A* Haploinsufficiency Causes Cognitive Impairment, Autism and Epileptic Encephalopathy with Mild Cerebellar Symptoms'. *European Journal of Human Genetics: EJHG* 23 (11): 1505–12. <https://doi.org/10.1038/ejhg.2015.21>.

- Ducros, Denier, Joutel, Vahedi, Michel, Darcel, Madigand, et al. 1999. 'Recurrence of the T666M Calcium Channel CACNA1A Gene Mutation in Familial Hemiplegic Migraine with Progressive Cerebellar Ataxia'. *American Journal of Human Genetics* 64 (1): 89–98. <https://doi.org/10.1086/302192>.
- Epi4K Consortium. 2016. 'De Novo Mutations in SLC1A2 and CACNA1A Are Important Causes of Epileptic Encephalopathies'. *American Journal of Human Genetics* 99 (2): 287–98. <https://doi.org/10.1016/j.ajhg.2016.06.003>.
- Hayashida, Takuya, Saito, Ishii, Yamada, Itakura, Minato, Fukuyama, Maegaki, and Hirose. 2018. 'CACNA1A-Related Early-Onset Encephalopathy with Myoclonic Epilepsy: A Case Report'. *Brain and Development* 40 (2): 130–33. <https://doi.org/10.1016/j.braindev.2017.08.006>.
- Kircher, Martin, Witten, Jain, O’Roak, Cooper, and Shendure. 2014. 'A General Framework for Estimating the Relative Pathogenicity of Human Genetic Variants'. *Nature Genetics* 46 (3): 310–15. <https://doi.org/10.1038/ng.2892>.
- Maksemous, Neven, Roy, Smith, and Griffiths. 2016. 'Next-Generation Sequencing Identifies Novel CACNA1A Gene Mutations in Episodic Ataxia Type 2'. *Molecular Genetics & Genomic Medicine* 4 (2): 211–22. <https://doi.org/10.1002/mgg3.196>.
- Ophoff, Roel, Terwindt, Vergouwe, van Eijk, Oefner, Hoffman, Lamerdin, et al. 1996. 'Familial Hemiplegic Migraine and Episodic Ataxia Type-2 Are Caused by Mutations in the Ca²⁺ Channel Gene CACNL1A4'. *Cell* 87 (3): 543–52. [https://doi.org/10.1016/S0092-8674\(00\)81373-2](https://doi.org/10.1016/S0092-8674(00)81373-2).
- Reinson, Karit, Öiglane-Shlik, Talvik, Vaher, Õunapuu, Ennok, Teek, et al. 2016. 'Biallelic CACNA1A Mutations Cause Early Onset Epileptic Encephalopathy with Progressive Cerebral, Cerebellar, and Optic Nerve Atrophy'. *American Journal of Medical Genetics. Part A* 170 (8): 2173–76. <https://doi.org/10.1002/ajmg.a.37678>.
- Zhang, Yi, Mori, Burgess, and Noebels. 2002. 'Mutations in High-Voltage-Activated Calcium Channel Genes Stimulate Low-Voltage-Activated Currents in Mouse Thalamic Relay Neurons'. *The Journal of Neuroscience: The Official Journal of the Society for Neuroscience* 22 (15): 6362–71. <https://doi.org/20026656>.
- Zhuchenko, Bailey, Bonnen, Ashizawa, Stockton, Amos, Dobyns, Subramony, Zoghbi, and Lee. 1997. 'Autosomal Dominant Cerebellar Ataxia (SCA6) Associated with Small Polyglutamine Expansions in the Alpha 1A-Voltage-Dependent Calcium Channel'. *Nature Genetics* 15 (1): 62–69. <https://doi.org/10.1038/ng0197-62>.



-  Epileptic encephalopathy
-  Episodic ataxia type 2
-  Intellectual disability
-  Ataxia
-  Epilepsy
-  Asymptomatic carrier of the *CACNA1A* pathogenic variant

* Carriers of the *CACNA1A* pathogenic variant

Fig 1. Pedigree. The family comprized of ten carriers of the *CACNA1A* pathogenic variants, with three asymptomatic carriers, from four generations.

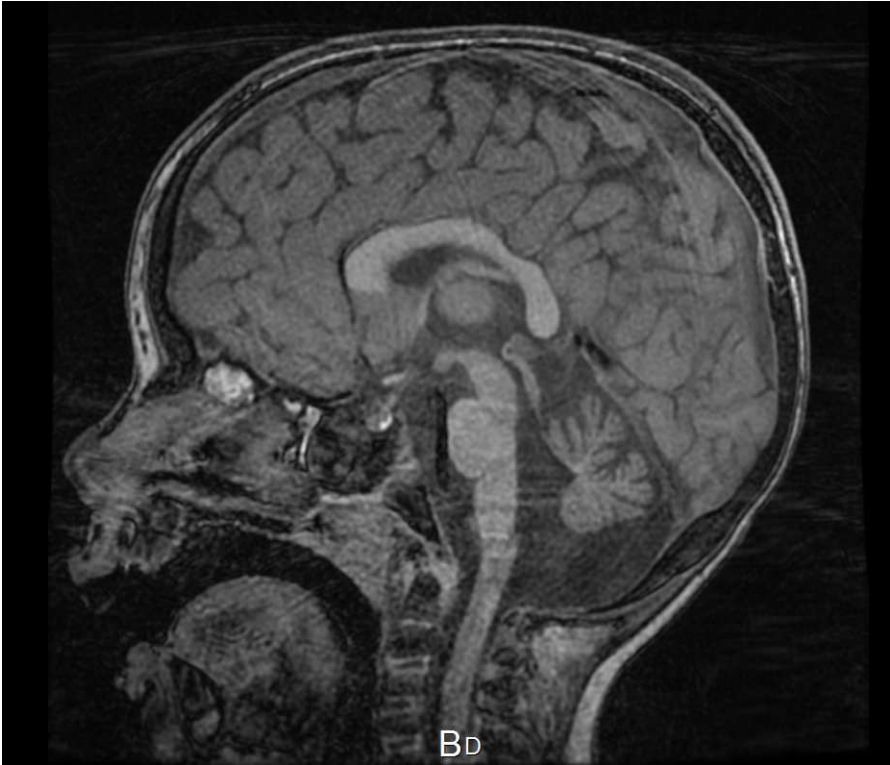

Fig 2. T1 Sagittal cross sectional brain MRI of index patient IV.1, with hypoplasia of the vermis